







Panax ginseng extract ameliorates methotrexate-induced multi-organ damage via the regulation of oxidative stress

Caglar MACİT¹ , Seren EDE-PAZARBASI² , Sümeyye YILMAZ-KARAOGLU² , Tugba TUNALI-AKBAY³ , Fatma Bedia KARAKAYA-ÇİMEN^{4,5,6} , Feriha ERCAN⁵ , Goksel SENER^{7*} 

¹ Department of Pharmacology, School of Pharmacy, İstanbul Medipol University, İstanbul, Turkey.

² Vocational School of Health Services, Fenerbahçe University, Ataşehir/İstanbul, Turkey.

³ Department of Basic Medical Sciences, Faculty of Dentistry, Marmara University, İstanbul, Turkey.

⁴ Department of Histology and Embryology, Institute of Health Science, Marmara University, İstanbul, Turkey.

⁵ Department of Histology and Embryology, School of Medicine, Marmara University, İstanbul, Turkey.

⁶ Department of Histology and Embryology, School of Medicine, Bezmialem Vakıf University, İstanbul, Turkey.

⁷ Department of Pharmacology, School of Pharmacy, Fenerbahçe University, Ataşehir/İstanbul, Turkey.

* Corresponding Author. E-mail: goksel.sener@fbu.edu.tr (G.S.); Tel. +90-533-762 07 11.

Received: 11 May 2023 / Revised: 19 July 2023 / Accepted: 13 August 2023

ABSTRACT: Oxidative damage plays an important role in organ toxicities caused by methotrexate (MTX). This study aimed to determine the antioxidant effects of *Panax ginseng* (PxG) extract against MTX-induced liver, lung, ileum and kidney damage. Twenty-four Sprague Dawley male rats (weight 250-300 g) were used in the study. The animals were randomly separated into three groups: a) Control, b) MTX-treated (MTX) and c) MTX+PxG-treated (MTX+PxG) groups. MTX was administered intraperitoneally at 20 mg/kg, as a single dose to MTX and MTX+PxG groups. PxG was administered orally at 100 mg/kg to the MTX+PxG group for five days. Saline was given to the control and MTX groups for 5 days. At the end of the experiment, liver, lung, ileum, and kidney samples were obtained. Malondialdehyde (MDA) and glutathione (GSH) levels, superoxide dismutase (SOD), glutathione-S-transferase (GST) and tissue factor (TF) activities were determined in all tissues. In addition, histological examinations were done through light microscopy. GraphPad Prism 5v. was used for statistics, and $p < 0.05$ were considered significant. Administration of MTX caused severe injury in tissues. Findings showed that MDA level, SOD, and GST activities were significantly normalized in the MTX+PxG group compared to the control group. A significant reduction in GSH level observed in the MTX group was reversed with PxG administration. In addition, TF activity and total protein levels were found to be impaired in the MTX group, but TF activity was significantly improved in liver and lung tissues and total protein level was significantly reversed in lung and ileum in MTX+PxG group. The results of histological examinations showed that MTX-induced damage was ameliorated with the PxG administration. In conclusion, this study shows that *Panax ginseng*, thanks to its antioxidant properties, reversed MTX-induced tissue damage and therefore may be beneficial against side effects in patients undergoing chemotherapy.

KEYWORDS: *Panax ginseng* extract; methotrexate; liver; lung; ileum; kidney; antioxidant activity.

1. INTRODUCTION

Methotrexate (MTX) is commonly used as a cytotoxic drug, especially in the treatment of leukemia and other malignancies [1]. It is also widely used in various inflammatory diseases such as rheumatoid arthritis and inflammatory bowel disease [2, 3]. However, its side effects limit its use. The cytotoxicity of MTX is nonselective for neoplastic cells. Unfortunately, it affects normal tissues that have highly proliferative cells, including the hematopoietic cells, and actively-dividing cells of the mucosa [4]. Furthermore, MTX was shown to have severe toxic impacts on vital organs like the liver, kidney, heart, and lung [5, 6]. The toxic effects of MTX mainly depend on its inhibitory effects on NAD(P)-dependent dehydrogenases and NADP malic enzymes [7]. In addition, since MTX has a high affinity to the dihydrofolate reductase enzyme, it suppresses DNA synthesis. During these two mechanisms, tissue damage occurs due to the production of free oxygen radicals.

It has been well known that oxygen is an essential element in our life. The use of oxygen is inevitable for every living cell. However, free radicals are produced by the mitochondria when oxygen is used. If the

How to cite this article: Macit C, Ede-Pazarbasi S, Yilmaz-Karaoglu S, Tunali-Akbay T, Karakaya-Çimen FB, Ercan F, Sener G. *Panax ginseng* extract ameliorates methotrexate-induced multi-organ damage via the regulation of oxidative stress. J Res Pharm. 2023; 27(5): 1974-1988.

sensitive balance between the production and elimination of free radical species is disturbed in favor of production, the accumulation of these products is observed [8]. Oxidative stress has an important role in aging and the emergence of chronic and degenerative illnesses such as cardiovascular disease, cancer and autoimmune disorders. To prevent the development of diseases and/or damage in the cells, endogenous and exogenous antioxidants have a significant free radical scavenging role [9, 10]. There are numerous exogenous antioxidants, including most phytonutrients such as pomegranate, blackberry, artichoke, strawberry, spinach, peas, and carrots. One of the plants with antioxidant properties is *Panax ginseng* (PxG), which has been researched since ancient times for its therapeutic effects [11].

Panax has come from a Greek word, *pan akheia*, meaning "cure of all diseases", usually has been cultivated in China and Korea. PxG (or Korean ginseng) grown in China and Korea has been widely used in traditional medicinal from ancient times [12]. The major effective components of PxG are saponins, also known as ginsenosides [13]. In addition, polysaccharides and polyacetylene alcohols are known as other effective components [14]. Recently, it has been demonstrated that PxG extract has antineoplastic, immunomodulatory, anti-inflammatory, anti-obesity, cardioprotective, antimicrobial, and neuroprotective impacts. The PxG extract is also used for its adaptogenic characteristics, as an antioxidant [11, 15, 16].

This study aimed to investigate methotrexate-induced tissue damage and possible protective effects of PxG on the liver, lung, ileum, and kidney damage in rats.

2. RESULTS

MTX administration significantly increased MDA levels in all tissues. PxG treatment significantly improved the MTX-induced increase in lipid peroxidation in lung and kidney tissues. Although MDA levels in the lung and kidney tissues were still higher than the control with PxG treatment, a significant decrease was found in all tissues compared to the MTX group ($p < 0.001$). The findings were shown in Figure 1.

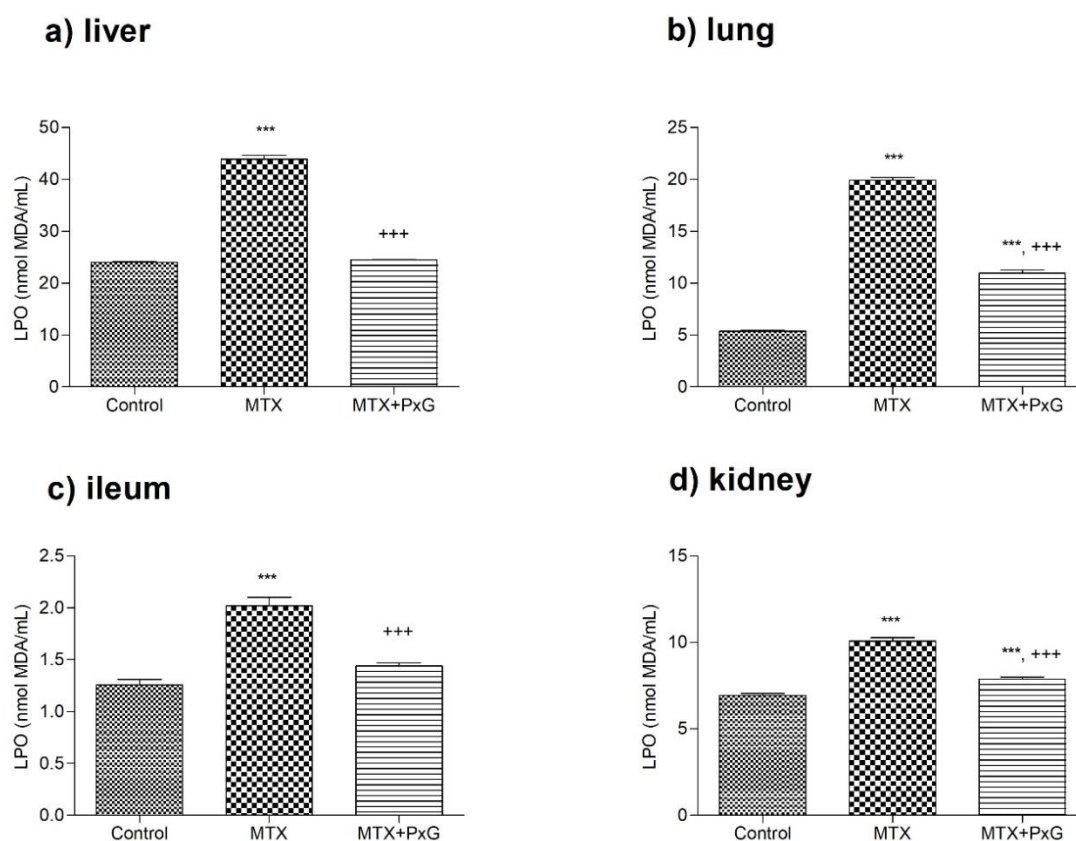


Figure 1. LPO in a) Liver, b) Lung, c) Ileum, d) Kidney tissues of the experimental groups (n=8 in each). C: Saline-treated control group; MTX: Methotrexate-treated group; MTX+PxG: Methotrexate and *Panax ginseng*-treated group.***: $p < 0.001$ compared to the control; +++: $p < 0.001$ compared to the MTX group.

Superoxide dismutase (SOD) activity changes in tissues were given in Figure 2. MTX administration significantly decreased SOD activity ($p < 0.001$) in all tissues. SOD activity was essentially increased in liver and lung tissues with PxG treatment compared to the control group ($p < 0.001$). PxG treatment significantly recovered SOD activity in liver, lung, ileum, and kidney tissues when compared to the MTX group ($p < 0.001$).

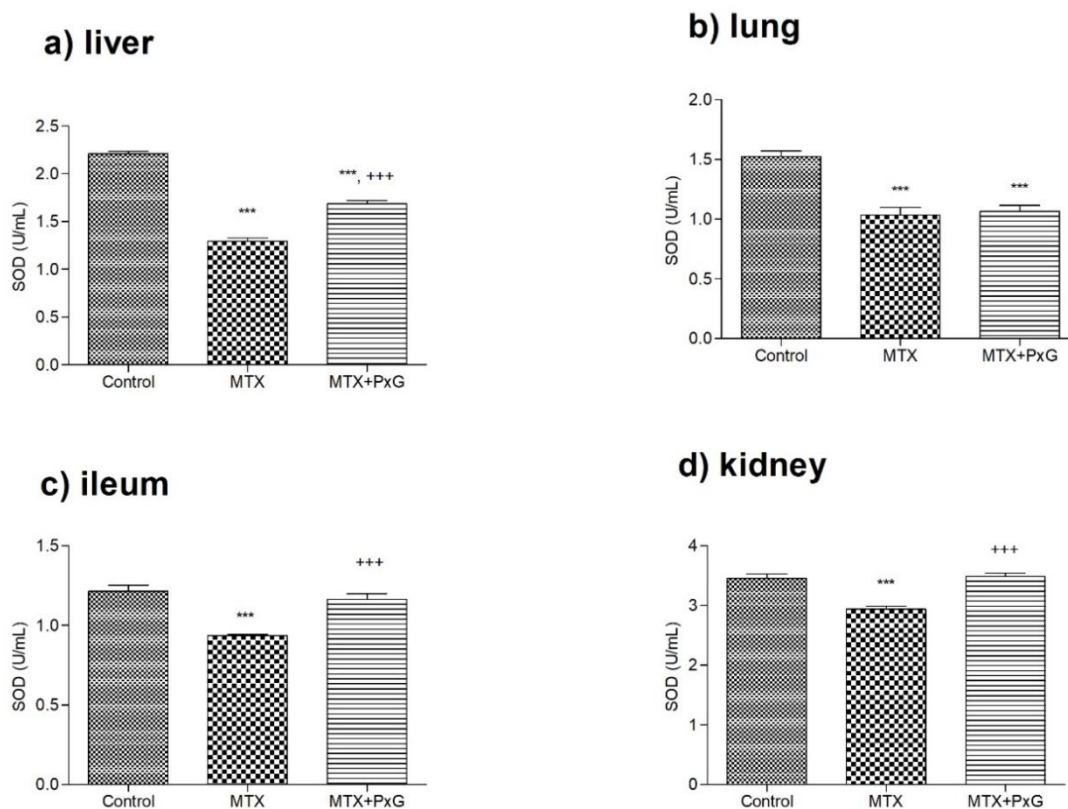


Figure 2. SOD activity in a) Liver, b) Lung, c) Ileum, d) Kidney tissues of the experimental groups (n=8 in each). C: Saline-treated control group; MTX: Methotrexate-treated group; MTX+PxG: Methotrexate plus *Panax ginseng*-treated group. ***: $p < 0.001$ when compared with the control group. +++: $p < 0.001$ compared to the MTX group.

MTX application significantly decreased the glutathione (GSH) level ($p < 0.001$) in all tissues compared to the control group. When compared to the MTX group, PxG treatment significantly improved GSH level ($p < 0.001$), in all tissues. However, PxG treatment was essentially normalized in the ileum and kidney tissues when compared to the control group, shown in Figure 3.

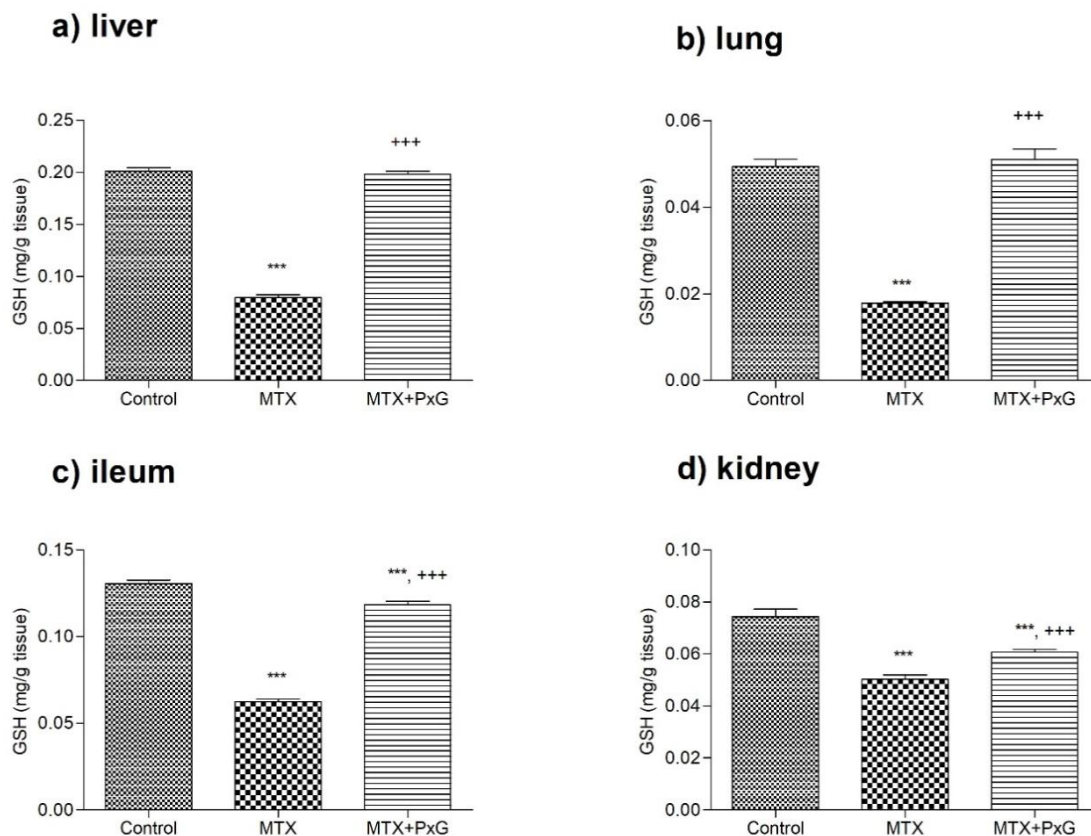


Figure 3. GSH levels in a) Liver, b) Lung, c) Ileum, d) Kidney tissues of the experimental groups (n=8 in each). C: Saline-treated control group; MTX: Methotrexate-treated group; MTX+PxG: Methotrexate plus *Panax ginseng*-treated group.***: $p < 0.001$ compared to the control; +: $p < 0.001$ compared to the MTX group.

As presented in Figure 4, glutathione-S transferase (GST) activity was significantly reduced in the MTX group in all tissues ($p < 0.001$) compared to the control group. PxG administration essentially improved the GST activity in all tissues when compared to the MTX group ($p < 0.001$).

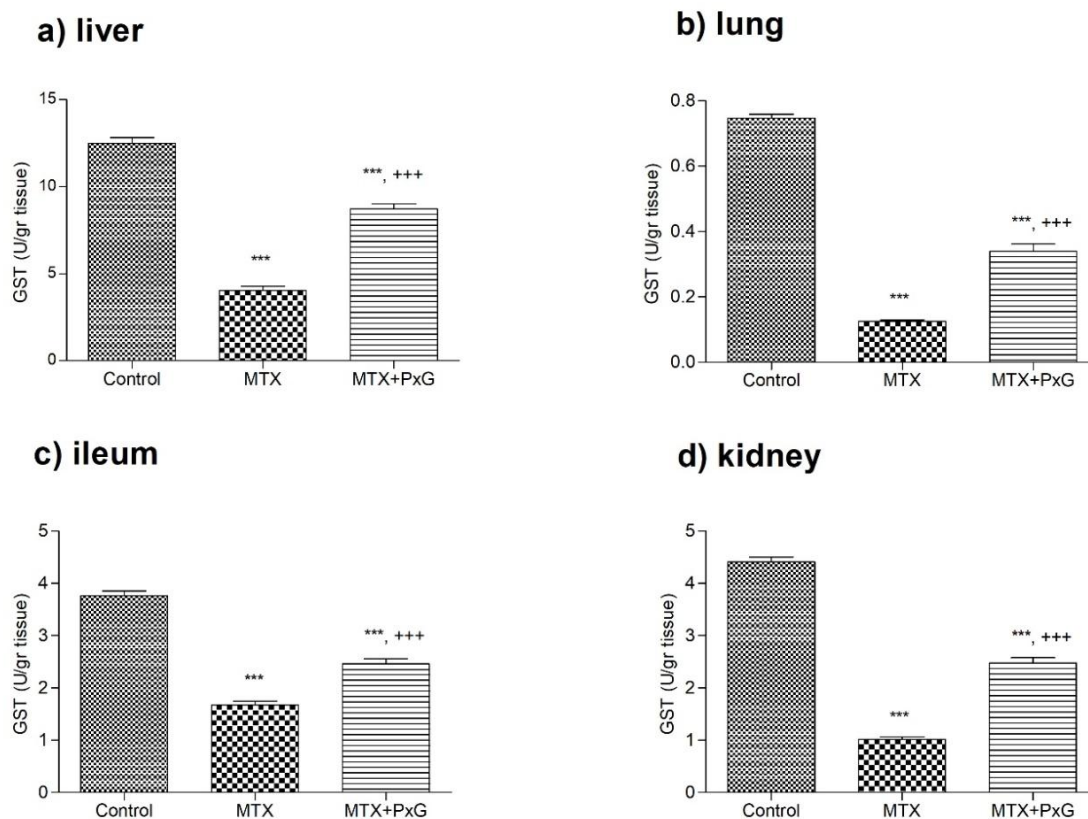


Figure 4. GST activity in a) Liver, b) Lung, c) Ileum, d) Kidney tissues of the experimental groups (n=8 in each). C: Saline-treated control group; MTX: Methotrexate-treated group; MTX+PxG: Methotrexate plus *Panax ginseng*-treated group.***: $p < 0.001$ compared to the control; +++: $p < 0.001$ compared to the MTX group.

MTX administration significantly increased tissue factor (TF) activity in liver tissue, decreased in lung tissue, and did not change in kidney tissue. PxG administration to the MTX group did not change. TF activity in related tissues was presented in Figure 5.

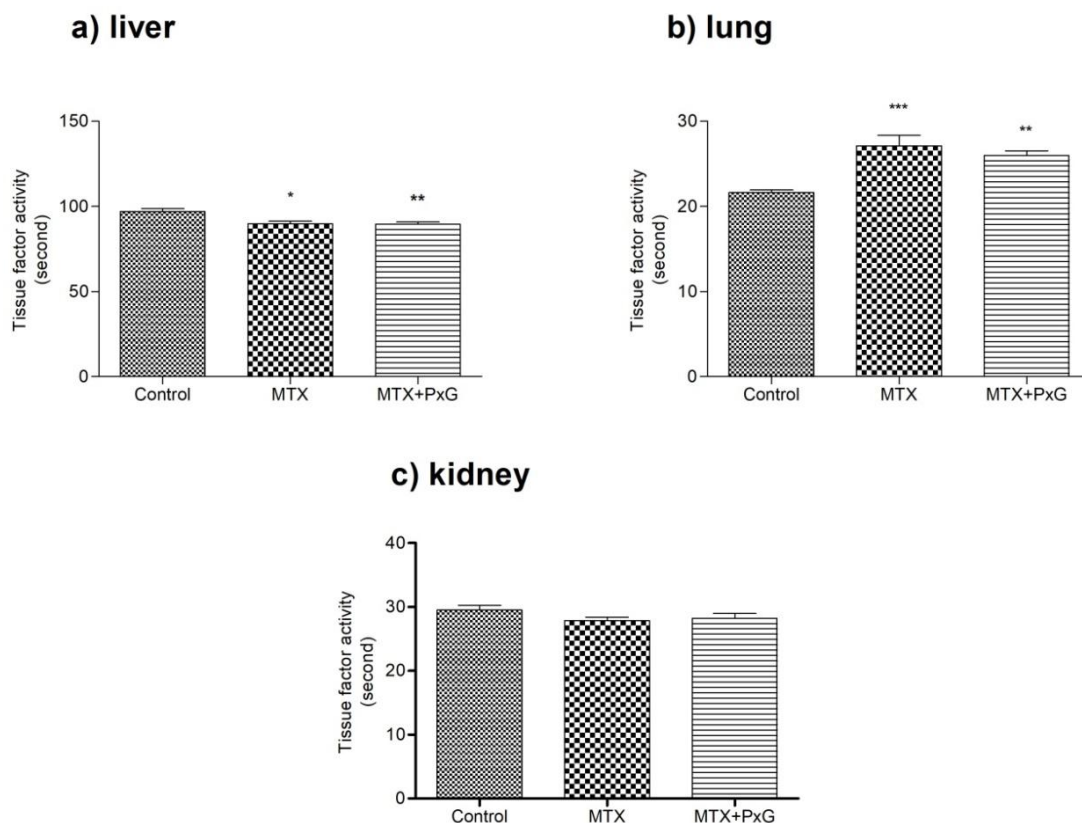


Figure 5. Tissue factor activity in a) Liver, b) Lung, and c) Kidney tissues of the experimental groups (n=8 in each). C: Saline-treated control group; MTX: Methotrexate-treated group; MTX+PxG: Methotrexate plus *Panax ginseng*-treated group. *: $p < 0.05$; **: $p < 0.01$ and ***: $p < 0.001$ when compared with control group.

Findings demonstrated that there were no significant changes in the total protein level with MTX treatment in all tissues. While PxG essentially improved total protein levels only lung and in ileum tissues according to the control group ($p < 0.05$), it was not essentially normalized total protein levels in liver and kidney tissues ($p > 0.05$). Findings can be seen in Figure 6.

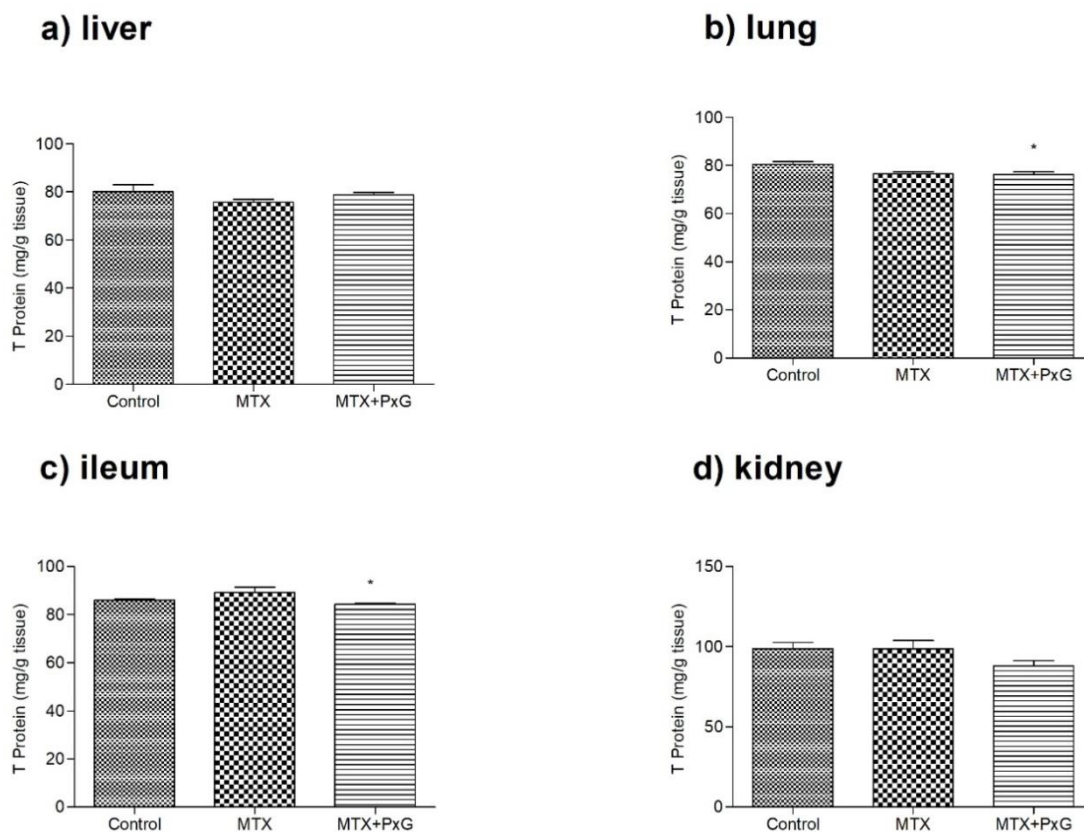


Figure 6. The total protein level in a) Liver, b) Lung, c) Ileum, and d) Kidney tissues of the experimental groups (n=8 in each). C: Saline-treated control group; MTX: Methotrexate-treated group; MTX+PxG: Methotrexate plus *Panax ginseng*-treated group. * p < 0.05: compared to the control group.

In histological evaluations, control groups demonstrated regular ileum, liver, lung, and kidney morphology in the control groups. Severe degeneration of villi with denudation of lamina propria and hemorrhage in the ileum, severe sinusoidal congestion and degenerated hepatocytes with perinuclear vacuolization in the liver, alveolar disturbance, bleeding and inflammatory cell infiltration in the lung, degeneration of renal corpuscles with cellular debris and dilatation of Bowman space, degenerated tubules and congestion in interstitial vessels of kidney were observed in the MTX group. Elongated villi formation with the decrease of epithelial degeneration in the ileum, mild sinusoidal congestion and decrease of degenerated hepatocytes in the liver, mild disturbances in alveoli and decrease of inflammatory cell infiltration in lung, a mild decrease of degenerated renal corpuscles, degenerated tubules and interstitial vascular congestion in kidney were observed in MTX+PxG group (Figure 7).

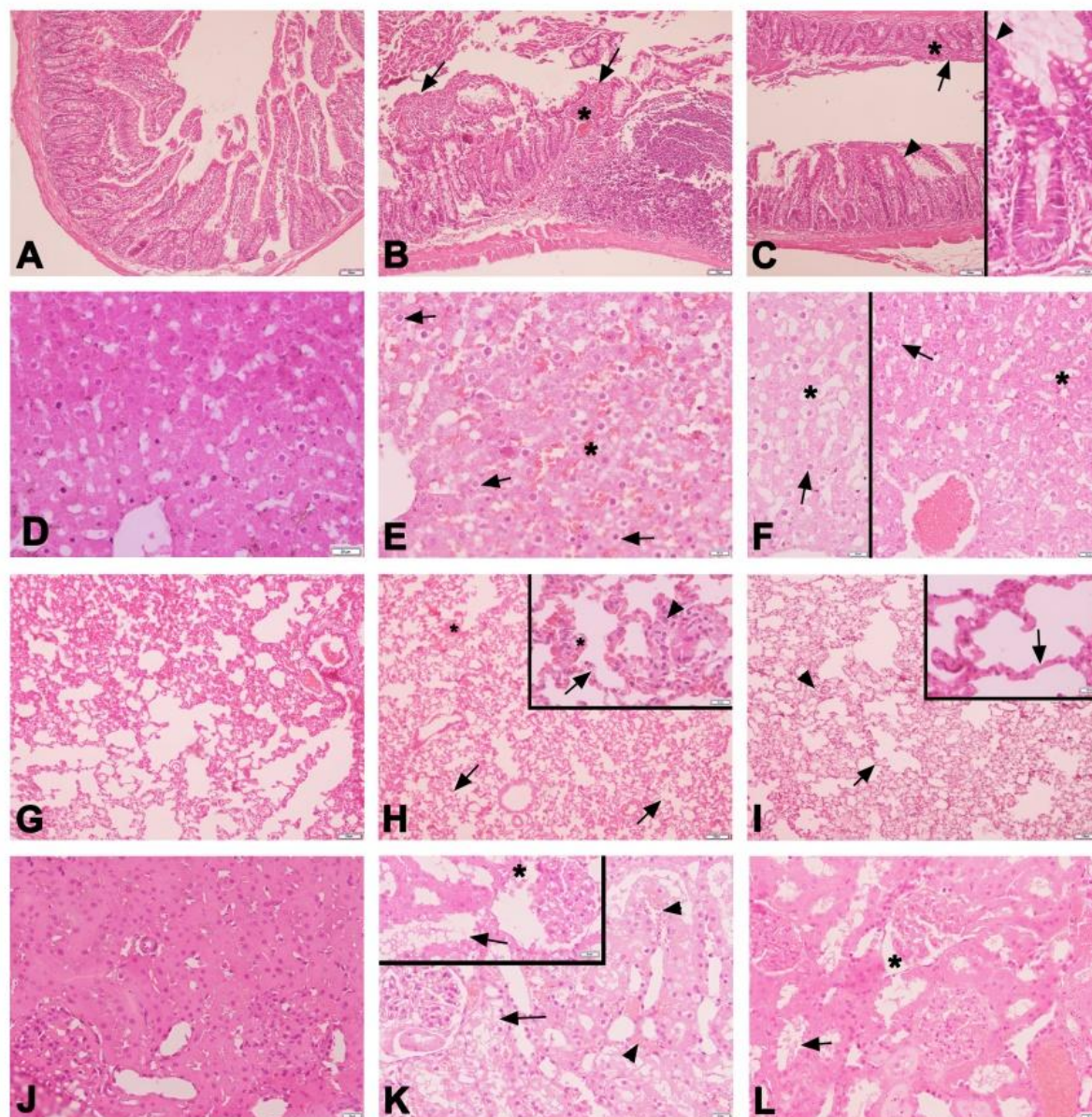


Figure 7. Representative H&E stained light micrographs of the ileum (A-C), liver (D-F), lung (G-I), and kidney (J-L) samples in the experimental groups. Regular morphology of the ileum (A), liver (D), lung (G), and kidney (J) are seen in the control group. Flattened villi formation with degenerated epithelium (arrow), denuded lamina propria, and hemorrhage (*) in the ileum (B); severe sinusoidal congestion (*) and degenerated hepatocytes (arrow) in the liver (E); alveolar disturbance (arrow), vascular congestion and hemorrhage (*) and inflammatory cells (arrowhead) in the lung (H); degenerated renal corpuscle with cellular debris and dilatation of Bowman space (*), degenerated tubule epithelium (arrow) and interstitial vascular congestion (arrowhead) in the kidney (K) are observed in the MTX group. Decreased flattened villi formation with degenerated epithelium (arrow), vascular congestion in lamina propria (*), increased elongated villi formation with regular epithelium (arrowhead) in the ileum (C); decreased vascular congestion (*) and degenerated hepatocytes (arrow) in the liver (F); mild alveolar disturbance (arrow), vascular congestion and decrease of inflammatory cells (arrowhead) in lung (I); the decrease of degenerated renal corpuscles with Bowman's space dilatation (*) and degenerated tubules (arrow) in the kidney (L) are observed in the MTX+PxG group.

3. DISCUSSION

MTX is a widely preferred antimetabolite agent in cancer therapy and leads to a reduction in DNA synthesis by primarily suppressing the proliferation of neoplastic cells [17]. Cytotoxic impacts of chronic MTX use were not restricted to neoplastic cells. Continuous MTX use also affects vital organs, including the lung, liver, kidney, and intestines [18]. The results of this study demonstrated that MTX administration to the rats

caused well-marked damage in all tissues. It has been known that the primary reason for damages induced by chronic use of MTX is oxidative stress [19]. On the other hand, it has been well known that *Panax ginseng* had beneficial active components, saponins known as ginsenosides, especially [20]. In a study investigating the antihepatotoxic and antioxidant effectiveness of *Panax ginseng* on chemotherapy-induced hepatotoxicity in experimental animals, findings demonstrated that PxG and its ginsenosides normalized liver function tests, improved antioxidant parameters and changed histology of liver of the rats [21]. Jahović et al. revealed that MTX-induced liver and kidney damage in rats was ameliorated with the melatonin treatment [22]. In another study investigating the depletion of GSH and antioxidant enzymes as well as elevation of lipid peroxidation (LPO) levels in the blood and liver of irradiated rats, it was observed that hydroalcoholic extract of PxG essentially improved and reduced the yield of LPO [23]. Based on these findings, it has shown that *Panax ginseng* is regarded as an alternative preventive agent for lipid peroxidation. Jang et al. (2015), showed intraperitoneal administration of high-dose ginseng extract improved decreased oxidative damage and cytokine levels in pulmonary fibrosis caused by high-dose radiation [24]. Consistent with the findings of previous studies, the current study demonstrated that the MTX increased the MDA level, and PxG administration decreased the MDA level in all tissues.

Another parameter examined in this study was SOD. SOD is an enzyme with antioxidant properties. It protects the body against free radicals. MTX usage reduces the SOD activity in the body resulting in the accumulation of reactive oxygen species [2]. Similar to the previous study, another study stated that silibinin administration reduced MTX-induced oxidative injury in lung tissue and results showed that SOD activity increased in the silibinin-treated group [25]. In a study, it was observed that gallic acid improved antioxidant parameters in MTX-induced liver and kidney toxicities in rats [26]. Song et al. highlighted the potential protective impacts of turmeric extract on intestinal mucosal barrier function in MTX-treated rats. Curcumin, primarily in turmeric extract, was explained as beneficial by the activation of the antioxidative mechanism of SOD [27]. In a previous study, water extract of PxG was studied on age-related oxidative stress and it was demonstrated that PxG essentially improved the oxidative parameters in aged rats [28]. It has been shown that PxG decreased the level of MDA and increased the expression of SOD and GPx in a rat model of global ischemia injury in the hippocampus [29]. In a different *in vitro* study, chemical profiling and antioxidant properties of red ginseng were investigated. Findings demonstrated that the root extract of red ginseng with water showed strong antioxidant activity by improving 2,2-diphenyl-1-picrylhydrazyl (DPPH) and (2,2'-azino-bis(3-ethylbenzothiazoline-6-sulfonic acid)) (ABTS) levels [30]. In accordance with the findings of the other studies, findings of this study confirmed that PxG has an antioxidant effect by scavenging ROS in animals treated with MTX.

Moreover, in an *in vitro* study investigating the anti-inflammatory and repair properties of human keratinocytes, Oh et al. confirmed that ginsenoside Re increased GSH level and SOD activity while decreasing ROS in HaCaT cells [31]. A different study investigating the effect of dose-dependent ferulic acid administration on antioxidant parameters has been demonstrated to have beneficial in MTX-induced hepatic damage in rats [32]. It has been known that MTX can cause pulmonary toxicity. It was observed that MTX treatment was associated with interstitial pulmonary disease resulting in cough [33]. In a study, it was shown ginsenosides protected pulmonary endothelium against ROS toxicity in rabbits [34]. In another study, examining the protective effect of ginsenoside-Rd in animals with acute renal failure, findings highlighted that SOD and CAT activities increased and MDA, BUN and serum creatinine levels decreased in nephrotoxic rats by the use of ginsenoside-Rd [35]. Similar to the obtained findings of other studies, observed results of the current study reported the possible antioxidant effect of PxG that improved GSH levels in animals with MTX-induced toxicities.

It was indicated that the primary mechanism of MTX-related oxidative distress is the augmentation of free radical content. GST is an enzyme with an antioxidant property that can scavenge free radical species. In the hepatotoxicity model induced by MTX in rats, it was determined that *Ginkgo biloba* increased the GSH level and GST activity, which were decreased by MTX administration [36]. Olayinka et al. showed the effectiveness of gallic acid on hepatorenal impairments caused by MTX in oxidative biomarkers in rats. It was reported that while hepatic GST activity was reduced in the MTX-treated rats when compared to the control group, pre-treatment and co-treatment of gallic acid improved GST activity in MTX-treated rats [26]. MTX causes pulmonary injury in the treatment of rheumatologic diseases [37, 38]. Ali et al. revealed that polydatin showed anti-oxidant, anti-inflammatory and anti-fibrotic effects in rats with MTX-induced pulmonary fibrosis [39]. In a study investigating the effect of Korean PxG on global and focal ischemia models in rats, it was demonstrated that Korean PxG reversed and improved GST, GPx and SOD activities in brain tissue [40]. In another study

conducted to investigate the effectiveness of PxG on hepatic antioxidant enzyme activities in cholesterol-fed rabbits, GST, GPx, CAT and SOD activities were examined. The findings indicated that the Ginseng administration reversed and improved the GST and SOD activities in animals [41]. Consistent with the observed findings of studies, the findings of the current study demonstrated that PxG normalized the activity of GST as well as other antioxidant markers in all examined tissues.

TF, also known as thromboplastin or Factor III, is an essential coagulation factor that starts the extrinsic blood coagulation cascade with factor VII. Because TF is not a stable protein some alterations lead to changes in its activity such as heating or the lipid peroxidation of the membrane due to oxidative stress [42]. In a previous study investigating the alpha-ketoglutarate effect on MTX-induced hepatic injury in animals, TF activity was reduced by alpha-ketoglutarate administration [43]. In another *in vitro* study, PxG was stated to possess an anti-coagulation effect [44]. In addition, the effectiveness of PxG herbal tablets was examined. The findings demonstrated that tablets have both protective properties and anti-oxidative effects on vascular endothelial cells, resulting in removed blood stasis syndrome [45, 46]. In a different study investigating the hepatoprotective effect of PxG, the oxidative radical scavenging effect of PxG was shown [47]. In rats with ischemia-induced renal damage, oral ginsenoside-Rd administration caused increases in the SOD, CAT and GPx activities and a decrease in the MDA, urea nitrogen, and creatinine concentrations in kidney tissue [48]. It was suggested that PG and its contents also have an antioxidant effect. In other studies related to the protective effect of PxG in cancer therapy, G-Rh2 administration was shown to prevent neoplastic cell migration and decrease tumor volume in rats treated with chemotherapeutic agents [49, 50]. In addition, previous studies showed that Rg-3 and Rg-2, major constituents of PxG, inhibited platelet aggregation and clotting factor FXa, and exhibited anti-coagulatory activities [51, 52, 53]. In the present study, MTX administration decreased TF activity of the lung tissue; this finding can be correlated to the bleeding tendency or the prevent embolism formation in the lung. PxG treatment increased the TF activity to normal levels. On the other hand, tissue factor activity increased in the liver of MTX-treated animals.

In a study investigating the antioxidant and organ protective effects of *Aralia taibaiensis*, it was demonstrated that the anti-oxidant effect was related to the saponin content of the plant, similar to PxG. In addition, it effectively improved organ injury in *in vivo* experiments [54]. In a different study, the anti-inflammatory and anti-oxidant effects of saikosaponin-d, an active ingredient extracted from *Bupleurum falcatum*, was investigated and it was reported that it has a hepatoprotective effect in liver injury by suppressing inflammatory responses, and acting as an anti-oxidant [55]. Parallel with the findings of oxidative stress parameters, histological findings showed that MTX-induced multi-organ damage was ameliorated with the antioxidant properties of the saponins in PxG

4. CONCLUSION

In conclusion, obtained data from this study support the hypothesis that PxG extract had potential anti-oxidant properties on MTX-induced tissue damage in rats. Findings demonstrated that while MTX treatment impaired oxidant-antioxidant balance, administration of PxG extract to MTX-induced rats significantly improved and normalized. Obtained results of the present study suggest that *Panax ginseng* can be considered a supportive therapeutic agent in preventing hepatorenal, pulmonary, and intestinal toxicities in patients under methotrexate treatment.

5. MATERIALS AND METHODS

5.1. Experimental Animals

All experimental protocols were approved by the Istanbul Medeniyet University, Science and Advanced Technologies Research Center (BILTAM), Laboratory Animal Care Unit (DEHAL) [25.03.2022 (2022/2-2)]. Twenty-four male Sprague Dawley rats (250–300 g, 3 months old) were obtained from BILTAM. Rats were kept at a constant temperature ($22 \pm 1^\circ\text{C}$), relative humidity (50–60%), and 12 h light-dark cycles. They were acclimatized with free access to tap water and regular chow. The rats were housed in the BILTAM and when working with experimental animals, it was studied in accordance to the institutional animal care and use committee guidelines.

5.2. Experimental Groups

Twenty-four animals were randomly assigned to the three groups (8 rats in each): Control, MTX and MTX+PxG. MTX was administered intraperitoneally at 20 mg/kg as a single dose to MTX and MTX+PxG

groups. Red Korean ginseng (*Panax ginseng*) root powder was obtained from Casel İlaç Sanayi and it was dissolved in saline [56]. PxG (100 mg/kg) was administered to the MTX+PxG group by oral gavage for five days [56, 57]. Saline was also given to the control and MTX groups orally, for 5 days [42, 43]. At the end of the fifth day, rats were decapitated followed by collecting the liver, lung, ileum and kidney tissue samples. Positive control group (PxG-treated healthy animals) was not included due to the results of previous studies [42, 56].

5.3. Biochemical Analysis

5.3.1. Glutathione determination

GSH level was determined by modifying Ellman's procedure (Beutler, 1975) [58]. Tissue homogenate on which deproteinization solution was added was centrifuged at 1500xg for 10 min. 0.5 mL of the supernatant was added to 2 ml of 0.3 mol/L Na₂HPO₄-2H₂O solution. 0.2 mL dithiobisnitrobenzoate (0.4 mg/mL, 1% sodium citrate) was added and incubated for 5 minutes. The absorbance was measured at 412 nm. GSH levels were calculated using an extinction coefficient of $1.36 \times 10^5 \text{ M}^{-1} \text{ cm}^{-1}$. Results were expressed in $\mu\text{mol GSH/g tissue}$.

5.3.2. Glutathione S-Transferase activity determination

GST activity was determined according to the method of Habig et al. (1981) [59]. Glutathione and 1-chloro-2,4-dinitro-benzene conjugation product was measured at 340 nm. The GST activity was calculated using the extinction coefficient ($9.6 \text{ mM}^{-1} \text{ cm}^{-1}$) obtained for the compound produced by the conjugation of glutathione and 1-chloro-2,4-dinitrobenzene. The results were expressed in U/g tissue.

5.3.3. Lipid peroxidation determination

Lipid peroxidation (LPO) in tissue homogenates was analyzed by the method of Ledwozyw (1986) [60]. A solution containing 0.375 g TBA and 15% TCA (prepared in 0.25 N HCl) was added to 0.5 mL homogenate. The samples were kept in a boiling water bath for 15 minutes followed by cooling and centrifuging. Then, the absorbance of samples was read at 532 nm. Results were expressed in nmol malondialdehyde (MDA)/mL tissue.

5.3.4. Superoxide dismutase activity determination

SOD activity in tissue homogenates was analyzed by the method of Mylorie and colleagues (1986) [61]. The absorbance of the color formed in the buffer prepared using 50 mM potassium phosphate buffer-EDTA, 0.2 mM riboflavin and 6 mM o-dianisidine and in the samples kept at 37 °C was read at 460 nm. Results were expressed as U/g tissue.

5.3.5. Tissue factor activity

Tissue Factor (TF) activities of liver, lung, and kidney tissues were evaluated according to Quick's one-stage method using normal plasma [62]. This was performed by mixing 0.1 mL liver homogenate with 0.1 mL of plasma, with the clotting reaction being started with the addition of 0.02 M CaCl₂. All reagents were in the reaction temperature (37°C) before admixture. TF activity was expressed as seconds.

5.3.6. Total protein

Total protein levels were measured according to the Lowry method (Lowry et al., 1951) [63] in experimental groups. The principle of this test is based on the measurement of the colored complex formed by the reduction of the Folin reagent by the Cu⁺² ions in the alkali protein solution in a spectrophotometer at 500 nm.

5.4. Histological Analysis

For the light microscopic evaluation of ileum, liver, lung, and kidney samples, tissues were fixed with 10% formaldehyde, dehydrated in ascending alcohol series, cleared in toluene and embedded in paraffin. Approximately 5 μm -thick paraffin sections were stained with hematoxylin and eosin (H&E) and examined under an Olympus BX51 photomicroscope (Tokyo, Japan).

5.5. Statistical Analysis

GraphPad Prism 5.0v. (GraphPad Software, San Diego, CA, USA) was used for analysis and findings were given as mean \pm SD (Standard Deviation). One-way Analysis of variance (ANOVA) followed by a post-hoc

Tukey test was performed to compare the multiple groups with each other. $p \leq 0.05$ was considered statistically significant.

Acknowledgements: The authors would like to thank the personnel of Istanbul Medeniyet University, Science and Advanced Technologies Research Center (IMU-BİLTAM), Laboratory Animal Care Unit (DEHAL) for their support.

Author contributions: Concept – G.S., T.T.A., F.E.; Design – G.S., C.M., T.T.A., F.E.; Supervision – G.S.; Resources – G.S., S.E.P., C.M., F.B.K., S.Y.K.; Materials – G.S., C.M.; Data Collection and/or Processing – S.Y.K., T.T.A., F.B.K., F.E.; Analysis and/or Interpretation – S.Y.K., T.T.A., F.B.K., F.E.; Literature Search – G.S., C.M., F.E., T.T.A., S.E.P.; Writing – C.M., G.S., T.T.A., F.E.; Critical Reviews – G.S., C.M., T.T.A., F.E.

Conflict of interest statement: The authors declared no conflict of interest.

REFERENCES

- [1] Bleyer WA. Methotrexate: clinical pharmacology, current status and therapeutic guidelines. *Cancer Treat Rev.* 1977;4(2): 87-101. [https://doi.org/10.1016/s0305-7372\(77\)80007-8](https://doi.org/10.1016/s0305-7372(77)80007-8)
- [2] Friedman B, Cronstein B. Methotrexate mechanism in treatment of rheumatoid arthritis. *Joint Bone Spine.* 2019;86(3): 301-307. <https://doi.org/10.1016/j.jbspin.2018.07.004>
- [3] AlAmeel T, Al Sulais E, Raine T. Methotrexate in inflammatory bowel disease: A primer for gastroenterologists. *Saudi J Gastroenterol.* 2022;28(4): 250-260. https://doi.org/10.4103/sjg.sjg_496_21
- [4] Çakır T, Özkan E, Dulundu E, Topaloğlu Ü, Şehirli AÖ, Ercan F, Şener E, Şener G. Caffeic acid phenethyl ester (CAPE) prevents methotrexate-induced hepatorenal oxidative injury in rats. *J Pharm Pharmacol.* 2011;63(12): 1566-1571. <https://doi.org/10.1111/j.2042-7158.2011.01359.x>
- [5] Al-Abkal F, Abdel-Wahab BA, El-Kareem HFA, Moustafa YM, Khodeer DM. Protective effect of pycnogenol against Methotrexate-Induced hepatic, renal, and cardiac toxicity: An in vivo study. *Pharmaceuticals (Basel).* 2022;15(6): 674. <https://doi.org/10.3390/ph15060674>
- [6] Kremer JM. Methotrexate pulmonary toxicity: Deep inspiration. *Arthritis Rheumatol.* 2020;72(12): 1959-1962. <https://doi.org/10.1002/art.41451>
- [7] Babiak RM, Campello AP, Carnieri EG, Oliveira MB. Methotrexate: pentose cycle and oxidative stress. *Cell Biochem Funct.* 1998;16(4): 283-293. [https://doi.org/10.1002/\(SICI\)1099-0844\(1998120\)16:4<283::AID-CBF801>3.0.CO;2-E](https://doi.org/10.1002/(SICI)1099-0844(1998120)16:4<283::AID-CBF801>3.0.CO;2-E)
- [8] Pham-Huy LA, He H, Pham-Huy C. Free radicals, antioxidants in disease and health. *Int J Biomed Sci.* 2008;4(2): 89-96.
- [9] McCall MR, Frei B. Can antioxidant vitamins materially reduce oxidative damage in humans?. *Free Radic Biol Med.* 1999;26(7-8): 1034-1053. [https://doi.org/10.1016/s0891-5849\(98\)00302-5](https://doi.org/10.1016/s0891-5849(98)00302-5)
- [10] Sies H, Stahl W, Sevanian A. Nutritional, dietary and postprandial oxidative stress. *J Nutr.* 2005;135(5): 969-972. <https://doi.org/10.1093/jn/135.5.969>
- [11] Mancuso C, Santangelo R. Panax ginseng and Panax quinquefolius: From pharmacology to toxicology. *Food Chem Toxicol.* 2017;107(Pt A): 362-372. <https://doi.org/10.1016/j.fct.2017.07.019>
- [12] Zhang H, Abid S, Ahn JC, Mathiyalagan R, Kim Y-J, Yang D-C, Wang Y. Characteristics of *Panax ginseng* cultivars in Korea and China. *Molecules.* 2020; 25(11): 2635. <https://doi.org/10.3390/molecules25112635>
- [13] Todorova V, Ivanov K, Ivanova S. Comparison between the biological active compounds in plants with adaptogenic properties (*Rhaponticum carthamoides*, *Lepidium meyenii*, *Eleutherococcus senticosus* and *Panax ginseng*). *Plants (Basel).* 2021;11(1): 64. <https://doi.org/10.3390/plants11010064>
- [14] Patel S, Rauf A. Adaptogenic herb ginseng (Panax) as medical food: Status quo and future prospects. *Biomed Pharmacother.* 2017;85: 120-127. <https://doi.org/10.1016/j.biopha.2016.11.112>
- [15] Dyshlyuk LS, Fotina NV, Milentyeva IS, Ivanova SA, Izgarysheva NV, Golubtsova YV. Antimicrobial and antioxidant activity of Panax ginseng and Hedysarum neglectum root crop extracts. *Braz J Biol.* 2022;84:e256944. <https://doi.org/10.1590/1519-6984.256944>
- [16] Ratan ZA, Youn SH, Kwak YS, Han CK, Haidere MF, Kim JK, Min H, Jung YJ, Hosseinzadeh H, Hyun SH, Cho JY. Adaptogenic effects of Panax ginseng on modulation of immune functions. *J Ginseng Res.* 2021;45(1): 32-40. <https://doi.org/10.1016/j.jgr.2020.09.004>

- [17] Çağlar Y, Özgür H, Matur I, Yenilmez ED, Tuli A, Gönlüşen G, Polat S. Ultrastructural evaluation of the effect of N-acetylcysteine on methotrexate nephrotoxicity in rats. *Histol Histopathol.* 2013;28(7): 865-874. <https://doi.org/10.14670/HH-28.865>
- [18] Hamed KM, Dighriri IM, Baomar AF, Alharthy BT, Alenazi FE, Alali GH, Alenazy RH, Alhumaidi NT, Alhulayfi DH, Alotaibi YB, Alhumaidan SS, Alhaddad ZA, Humadi AA, Alzahrani SA, Alobaid RH. Overview of methotrexate toxicity: A comprehensive literature review. *Cureus.* 2022;14(9): e29518. <https://doi.org/10.7759/cureus.29518>
- [19] Demiryilmaz I, Uzkeser H, Cetin N, Hacimuftuoglu A, Bakan E, Altuner D. Effect of mirtazapine on gastric oxidative stress and DNA injury created with methotrexate in rats. *Asian J. Chem.* 2013;25(4): 2047-2050. <https://doi.org/10.14233/ajchem.2013.13296>
- [20] Lee YM, Yoon H, Park HM, Song BC, Yeum KJ. Implications of red Panax ginseng in oxidative stress associated chronic diseases. *J Ginseng Res.* 2017;41(2): 113-119. <https://doi.org/10.1016/j.jgr.2016.03.003>
- [21] Huang H, Chen F, Long R, Huang G. The antioxidant activities in vivo of bitter gourd polysaccharide. *Int J Biol Macromol.* 2020;145: 141-144. <https://doi.org/10.1016/j.ijbiomac.2019.12.165>
- [22] Jahovic N, Çevik H, Şehirli AÖ, Yeğen BÇ, Şener G. Melatonin prevents methotrexate-induced hepatorenal oxidative injury in rats. *J Pineal Res.* 2003;34: 282-287. <https://doi.org/10.1034/j.1600-079X.2003.00043.x>
- [23] Verma P, Jahan S, Kim TH, Goyal PK. Management of radiation injuries by Panax ginseng extract. *J Ginseng Res.* 2011;35(3): 261-271. <https://doi.org/10.5142/jgr.2011.35.3.261>
- [24] Jang SS, Kim HG, Han JM, Lee JS, Choi MK, Huh GJ, Son CG. Modulation of radiation-induced alterations in oxidative stress and cytokine expression in lung tissue by Panax ginseng extract. *Phytother Res.* 2015;29(2): 201-209. <https://doi.org/10.1002/ptr.5223>
- [25] Kalemci S, Topal Y, Celik SY, Yilmaz N, Beydilli H, Kosar MI, Dirican N, Altuntas I. Silibinin attenuates methotrexate-induced pulmonary injury by targeting oxidative stress. *Exp Ther Med.* 2015;10(2): 503-507. <https://doi.org/10.3892/etm.2015.2542>
- [26] Olayinka ET, Ore A, Adeyemo OA, Ola OS. Ameliorative effect of gallic acid on methotrexate-induced hepatotoxicity and nephrotoxicity in rat. *J Xenobiot.* 2016;6(1): 6092. <https://doi.org/10.4081/xeno.2016.6092>
- [27] Song WB, Wang YY, Meng FS, Zhang QH, Zeng JY, Xiao LP, Yu XP, Peng DD, Su L, Xiao B, Zhang ZS. Curcumin protects intestinal mucosal barrier function of rat enteritis via activation of MKP-1 and attenuation of p38 and NF-κB activation. *PLoS One.* 2010;5(9): e12969. <https://doi.org/10.1371/journal.pone.0012969>
- [28] Ramesh T, Kim SW, Hwang SY, Sohn SH, Yoo SK, Kim SK. Panax ginseng reduces oxidative stress and restores antioxidant capacity in aged rats. *Nutr Res.* 2012;32(9): 718-726. <https://doi.org/10.1016/j.nutres.2012.08.005>
- [29] Kim YO, Kim HJ, Kim GS, Park HG, Lim SJ, Seong NS, Ham YW, Lee SD, Jang KH, Jung KH, Chung JH, Kang SA. Panax ginseng protects against global ischemia injury in rat hippocampus. *J Med Food.* 2009;12(1): 71-76. <https://doi.org/10.1089/jmf.2007.0614>
- [30] Zhang HE, Chu MY, Jiang T, Song XH, Hou JF, Cheng LY, Feng Y, Chen CB, Wang EP. By-Product of the Red Ginseng Manufacturing Process as Potential Material for Use as Cosmetics: Chemical Profiling and In Vitro Antioxidant and Whitening Activities. *Molecules.* 2022;27(23): 8202. <https://doi.org/10.3390/molecules27238202>
- [31] Colombo I, Sangiovanni E, Maggio R, Mattozzi C, Zava S, Corbett Y, Fumagalli M, Carlino C, Corsetto PA, Scaccabarozzi D, Calvieri S, Gismondi A, Taramelli D, Dell'Agli M. HaCaT Cells as a Reliable In Vitro Differentiation Model to Dissect the Inflammatory/Repair Response of Human Keratinocytes. *Mediators Inflamm.* 2017;7435621. <https://doi.org/10.1155/2017/7435621>
- [32] Roghani M, Kalantari H, Khodayar MJ, Khorsandi L, Kalantar M, Goudarzi M, Kalantar H. Alleviation of Liver Dysfunction, Oxidative Stress and Inflammation Underlies the Protective Effect of Ferulic Acid in Methotrexate-Induced Hepatotoxicity. *Drug Des Devel Ther.* 2020;14: 1933-1941. <https://doi.org/10.2147/DDDT.S237107>
- [33] Karadag AS, Kanbay A, Ozlu E, Uzuncakmak TK, Gedik C, Akdeniz N. Pulmonary fibrosis developed secondary to methotrexate use in a patient with psoriasis vulgaris. *North Clin Istanbul.* 2015;2(2): 159-161. <https://doi.org/10.14744/nci.2015.97759>
- [34] Gillis CN. Panax ginseng pharmacology: a nitric oxide link? *Biochem Pharmacol.* 1997;54(1): 1-8. [https://doi.org/10.1016/s0006-2952\(97\)00193-7](https://doi.org/10.1016/s0006-2952(97)00193-7)
- [35] Yokozawa T, Liu ZW. The role of ginsenoside-Rd in cisplatin-induced acute renal failure. *Ren Fail.* 2000;22(2):115-127. <https://doi.org/10.1081/jdi-100100858>

- [36] Al Kury LT, Dayyan F, Ali Shah F, Malik Z, Khalil AAK, Alattar A, Alshaman R, Ali A, Khan Z. Ginkgo biloba extract protects against methotrexate-induced hepatotoxicity: a computational and pharmacological approach. *Molecules*. 2020; 25(11): 2540. <https://doi.org/10.3390/molecules25112540>
- [37] Kalemci S, Akpınar O, Dere Y, Sarihan A, Zeybek A, Tanrıverdi Ö. Efficacy of clarithromycin as a protective agent in the methotrexate-induced pulmonary fibrosis model. *Kardiocir Torakochirurgia Pol*. 2018;15(4): 209-212. <https://doi.org/10.5114/kitp.2018.80915>
- [38] Swierkot J, Szechiński J. Methotrexate in rheumatoid arthritis. *Pharmacol Rep*. 2006;58(4): 473-492.
- [39] Ali YA, Ahmed AAE, Abd El-Raouf OM, Elkhoely A, Gad AM. Polydatin combats methotrexate-induced pulmonary fibrosis in rats: Involvement of biochemical and histopathological assessment. *J Biochem Mol Toxicol*. 2022;36(5): e23019. <https://doi.org/10.1002/jbt.23019>
- [40] Shah ZA, Gilani RA, Sharma P, Vohora SB. Cerebroprotective effect of Korean ginseng tea against global and focal models of ischemia in rats. *J Ethnopharmacol*. 2005;101(1-3): 299-307. <https://doi.org/10.1016/j.jep.2005.05.002>
- [41] Lee L-S, Cho C-W, Hong H-D, Lee Y-C, Choi U-K, Kim Y-C. Hypolipidemic and antioxidant properties of phenolic compound-rich extracts from white ginseng (*Panax ginseng*) in cholesterol-fed rabbits. *Molecules*. 2013; 18(10): 12548-12560. <https://doi.org/10.3390/molecules181012548>
- [42] Tunali-Akbay T, Sehırlı O, Ercan F, Sener G. Resveratrol protects against methotrexate-induced hepatic injury in rats. *J Pharm Pharm Sci*. 2010;13(2): 303-310. <https://doi.org/10.18433/j30k5q>
- [43] Mehra L, Bhattacharya A, Rawat H, Kumar A, Jaimini A, Mittal G. In-vitro and in-vivo functional observation studies to establish therapeutic potential of alpha-ketoglutarate against methotrexate induced liver injury. *Biomed J*. 2021;44(5):611-619. <https://doi.org/10.1016/j.bj.2020.05.012>
- [44] Li CT, Wang HB, Xu BJ. A comparative study on anticoagulant activities of three Chinese herbal medicines from the genus *Panax* and anticoagulant activities of ginsenosides Rg1 and Rg2. *Pharm Biol*. 2013;51(8): 1077-1080. <https://doi.org/10.3109/13880209.2013.775164>
- [45] Xiong L, Xie J, Song C, Liu J, Zheng J, Liu C, Zhang X, Li P, Wang F. The activation of Nrf2 and its downstream regulated genes mediates the antioxidative activities of Xueshuan Xinmaining tablet in human umbilical vein endothelial cells. *Evid Based Complement Alternat Med*. 2015;2015: 187265. <https://doi.org/10.1155/2015/187265>
- [46] Zhang X, Zhang C, Sai J, Li F, Liu J, Li Y, Wang F. Xueshuan Xinmaining tablet treats blood stasis through regulating the expression of F13a1, Car1, and Tbx2r. *Evid Based Complement Alternat Med*. 2015;2015: 704390. <https://doi.org/10.1155/2015/704390>
- [47] Wee JJ, Hoe JN, Kim MW, Kang DY. Protective of korean red ginseng against oxidative damage by carbon tetrachloride in rat. *Korean J Ginseng Sci*. 1996;20(2): 154-158 <https://koreascience.kr/article/JAKO199611919373271.pdf>
- [48] Yokozawa T, Liu ZW, Dong E. A study of ginsenoside-Rd in a renal ischemiareperfusion model. *Nephron* 1998;78(2): 201-206. <https://doi.org/10.1159/000044911>
- [49] Rubio-Patiño C, Bossowski JP, De Donatis GM, Mondragón L, Villa E, Aira LE, Chiche J, Mhaidly R, Lebeau-pin C, Marchetti S, Voutetakis K, Chatziioannou A, Castelli FA, Lamourette P, Chu-Van E, Fenaille F, Avril T, Passeron T, Patterson JB, Verhoeyen E, Bailly-Maitre B, Chevet E, Ricci JE. Low-protein diet induces ire1alpha-dependent anticancer immunosurveillance. *Cell Metab*. 2018, 27, 828–842. <https://doi.org/10.1016/j.cmet.2018.02.009>
- [50] Ge G, Yan Y, Cai H. Ginsenoside Rh2 inhibited proliferation by inducing ROS mediated ER stress dependent apoptosis in lung cancer cells. *Biol. Pharm. Bull*. 2017, 40, 2117–2124. <https://doi.org/10.1248/bpb.b17-00463>
- [51] Saba E, Jeong D, Irfan M, Lee YY, Park S-, Park C-, Rhee MH. Anti-inflammatory activity of Rg3-enriched korean red ginseng extract in murine model of sepsis. *Evid -Based Complement Altern Med*. 2018;2018. <https://doi.org/10.1155/2018/6874692>
- [52] Xiong L, Qi Z, Zheng B, Li Z, Wang F, Liu J, Li P. Inhibitory effect of triterpenoids from panax ginseng on coagulation factor X. *Molecules* 2017;22(4): 649. <https://doi.org/10.3390/molecules22040649>
- [53] Li C, Wang H, Xu B. A comparative study on anticoagulant activities of three Chinese herbal medicines from the genus *Panax* and anticoagulant activities of ginsenosides Rg1 and Rg2. *Pharm Biol* 2013;51(8): 1077e80. <https://doi.org/10.3109/13880209.2013.775164>
- [54] Li H, Zhai B, Sun J, Fan Y, Zou J, Cheng J, Zhang X, Shi Y, Guo D. Antioxidant, Anti-Aging and Organ Protective Effects of Total Saponins from *Aralia taibaiensis*. *Drug Des Devel Ther*. 2021;15: 4025-4042. <https://doi.org/10.2147/DDDT.S330222>

- [55] Chang GR, Lin WL, Lin TC, Liao HJ, Lu YW. The Ameliorative Effects of Saikosaponin in Thioacetamide-Induced Liver Injury and Non-Alcoholic Fatty Liver Disease in Mice. *Int J Mol Sci.* 2021;22(21): 11383. <https://doi.org/10.3390/ijms222111383>
- [56] Karakaya-Çimen FB, Macit Ç, Göksun Sivas G, Tunalı Akbay T, Şener G, Ercan F. Morphological and Biochemical Investigation of the Protective Effects of *Panax ginseng* on Methotrexate-Induced Testicular Damage. *Eur J Biol* 2023;82(1): 31-37. <https://doi.org/10.26650/EurJBiol.2023.1271825>
- [57] Hussien M, Yousef MI. Impact of ginseng on neurotoxicity induced by cisplatin in rats. *Environ Sci Pollut Res Int.* 2022;29(41): 62042-62054. <https://doi.org/10.1007/s11356-021-16403-y>
- [58] Beutler E, Reduced Glutathione (GSH). In: Bergmeyer HV. (Ed). *Red Blood Cell Metabolism: A Manual of Biochemical Methods.* Grune and Stratton, New York, 1975, pp.112-114.
- [59] Habig WH, Jacoby WB. Assays for differentiation of glutathione-S-transferases. *Methods Enzymol.* 1981;77: 398-405. [https://doi.org/10.1016/s0076-6879\(81\)77053-8](https://doi.org/10.1016/s0076-6879(81)77053-8)
- [60] Ledwozyw A, Michalak J, Stepień A, Kadziolka A. The relationship between plasma triglycerides, cholesterol, total lipids and lipid peroxidation products during human atherosclerosis. *Clin Chim Acta; Int J Clin Chem.* 1986;155(3): 275-283. [https://doi.org/10.1016/0009-8981\(86\)90247-0](https://doi.org/10.1016/0009-8981(86)90247-0)
- [61] Mylroie AA, Collins H, Umbles C, Kyle J. Erythrocyte superoxide dismutase activity and other parameters of copper status in rats ingesting lead acetate. *Toxicol Appl Pharmacol.* 1986;82(3): 512-20. [https://doi.org/10.1016/0041-008x\(86\)90286-3](https://doi.org/10.1016/0041-008x(86)90286-3)
- [62] Ingram GI, Hills M. Reference method for the one-stage prothrombin-time test on human blood. *Thromb Haemost.* 1976; 36(1): 237-238.
- [63] Lowry OH, Rosebrough NJ, Farr AL, Randall RJ. Protein measurement with folin phenol reagent. *J Biol Chem.* 1951; 193(1): 265-275.